

**PennHIP Report**

Referring Veterinarian: Dr Christopher Tate Email: vets@clvets.com	Clinic Name: Cleary Lake Veterinary Hospital Clinic Address: 18577 Natchez Ave Prior Lake, MN 55372 Phone: (952) 435-8387 Fax: (952) 435-8777
---	---

**Patient Information**

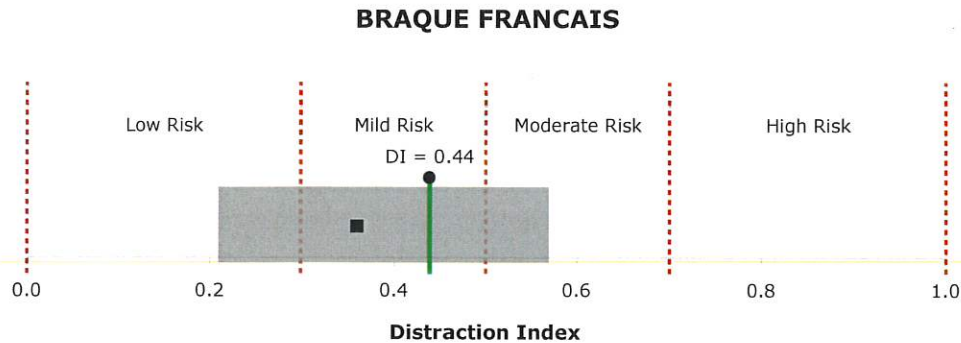
Client: Kreklow, Kyle Patient Name: PIXI DE LA BAIE DE MYRTHE Reg. Name: PIXI DE LA BAIE DE MYRTHE PennHIP Num: 154183 Species: Canine Date of Birth: 02 Oct 2019 Sex: Female Date of Study: 17 Mar 2021 Date of Report: 22 Mar 2021	Tattoo Num: Patient ID: KREKLOW PIXI Registration Num: BF-001101 Microchip Num: 250268723030499 Breed: BRAQUE FRANCAIS Age: 17 months Weight: 34.3 lbs/15.6 kgs Date Submitted: 17 Mar 2021
--	--

**Findings**

Distraction Index (DI): Right DI = 0.44, Left DI = 0.34.  
 Osteoarthritis (OA): **No radiographic evidence of OA for either hip.**  
 Cavitation/Other Findings: No cavitation present.

**Interpretation**

Distraction Index (DI): The laxity ranking is based on the hip with the greater laxity (larger DI). In this case the DI used is 0.44.  
 OA Risk Category: The DI is between 0.31 and 0.49. This patient is at mild risk for hip OA.  
 Distraction Index Chart:



**BREED STATISTICS:** This interpretation is based on a cross-section of 43 canine patients of the BRAQUE FRANCAIS breed in the AIS PennHIP database. The gray strip represents the central 90% range of DIs (0.21 - 0.57) for the breed. The breed average DI is 0.36 (solid square). The patient DI is the solid circle (0.44).

**SUMMARY:** The degree of laxity (DI = 0.44) falls within the central 90% range of DIs for the breed. This amount of hip laxity places the hip at a mild risk to develop hip OA. **No radiographic evidence of OA for either hip.**